


Dome-Based Modification of Double Osteotomy for the First Metatarsal

 Kürşad Aytekin

Department of Orthopedics and Traumatology, Department of Anatomy, Giresun, Türkiye

ABSTRACT

Congruence of the first metatarsophalangeal joint in hallux valgus (HV) is often associated with an increased distal metatarsal articular angle. Double osteotomy is typically recommended for cases of hallux valgus with congruent joints and a high intermetatarsal angle (IMA). However, conventional open- or closed-wedge osteotomies are frequently ineffective, as they may not adequately correct a high IMA. We propose a novel dome-based osteotomy technique for both the distal and proximal metaphysis of metatarsal bones to surgically correct HV deformity. Preoperative and postoperative assessments were conducted using the American Orthopaedic Foot & Ankle Society Metatarsophalangeal-Interphalangeal Score (AOFAS MTP-IP) score and radiological measurements, including the hallux valgus angle, intermetatarsal angle, and metatarsal articular angle. The AOFAS MTP-IP score improved from 28 preoperatively to 82 postoperatively. Radiological parameters also improved to within normal ranges. The novelty of this technique lies in the configuration of the distal metatarsal osteotomy. The primary advantage is enhanced stability due to increased contact surface area.

Keywords: Distal metatarsal articular angle, dome osteotomy, double osteotomy, hallux valgus, reverse L osteotomy.



Cite this article as:

Aytekin K. Dome-Based Modification of Double Osteotomy for the First Metatarsal. Orthop Surg Trauma 2025;1(1):27–30.

Address for correspondence:

Kürşad Aytekin.
Department of Orthopedics and Traumatology, Department of Anatomy, Giresun, Türkiye
E-mail:
kursadaytekin@gmail.com

Submitted: 25.10.2024

Revised: 18.01.2025

Accepted: 16.03.2025

Available Online: 29.04.2025

Ethics: Giresun Traning and Research Hospital Ethics Committee (Approval Number: E-53593568-771-254354756, Date: 24.09.2024).

Conflict of Interest: None.

Funding: None.

Orthopedic Surgery & Trauma -
Available online at www.ortst.org

INTRODUCTION

Hallux valgus (HV) with congruence of the first metatarsophalangeal joint (MTPJ) is characterized by an increased distal metatarsal articular angle (DMAA). Maintaining joint congruency during surgical correction is crucial, as misalignment may result in pain, stiffness, or arthrosis. Simultaneous correction of both the intermetatarsal angle (IMA) and the DMAA typically requires two osteotomies.^[1]

The double osteotomy technique was first described by Peterson and Newman in 1993 to address both IMA and DMAA. It involves an open-wedge osteotomy at the proximal metatarsal and a closed-wedge osteotomy at the distal metatarsal.^[1] However, traditional open or closed wedge techniques have several disadvantages, including instability, the need for grafting, and alteration of metatarsal length. The technique proposed in this study aims to provide a more stable solution for double osteotomy of the first metatarsal in HV with a congruent first metatarsophalangeal joint, without requiring grafts and without altering the length of the first metatarsal. In comparison to traditional wedge osteotomies, dome osteotomies offer enhanced stability,^[2] along with additional benefits such as preservation of metatarsal length and elimination of the need for grafting.

This presentation aims to describe the outcome of an HV case with a congruent joint, managed using a modified approach to double metatarsal osteotomy. In this technique, a complete dome osteotomy was performed on the proximal metatarsal, while a dome osteotomy of the dorsal



This work is licensed under a Creative Commons Attribution-NonCommercial 4.0 International License.

cortex combined with an axial plane osteotomy of the plantar cortex was performed on the distal metatarsal.

CASE REPORT

Ethics approval was obtained from the Giresun Traning and Research Hospital Ethics Committee (Approval Number: E-53593568-771-254354756, Date: 24.09.2024). A 46-year-old female patient presented to the orthopedic outpatient clinic with bunion-related pain and difficulty wearing shoes. Previous interventions, including shoe modifications and medical treatment, provided insufficient relief. Weight-bearing anteroposterior and lateral foot X-rays revealed an IMA of 16° , a hallux valgus angle (HVA) of 30° , and a DMAA of 31° (Fig. 1). The case was classified as moderate hallux valgus based on severity stratification.^[3] The

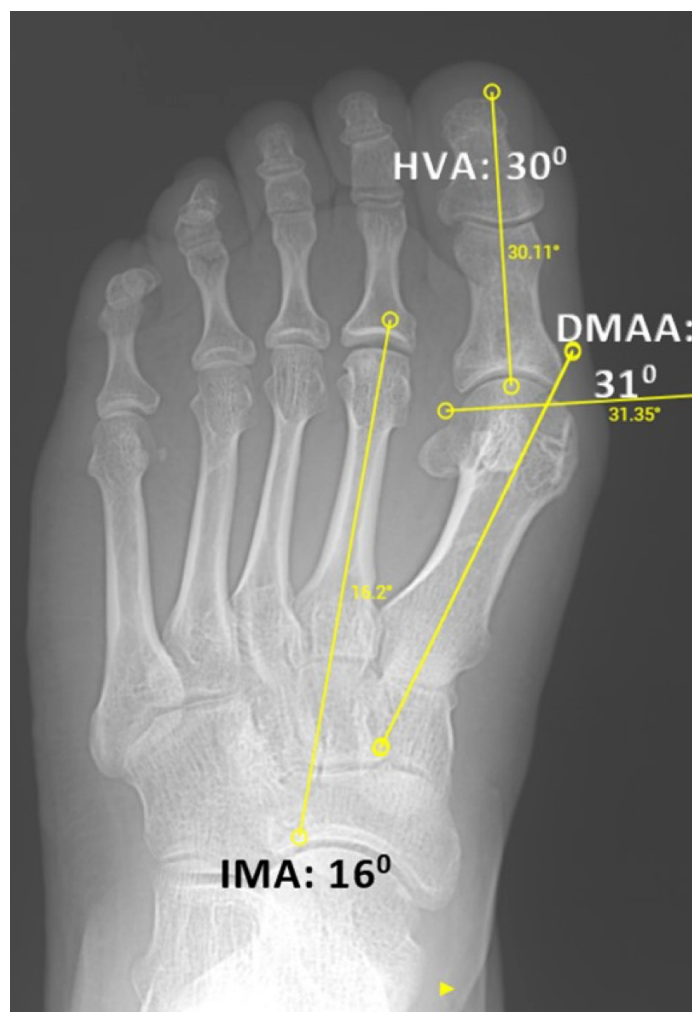


Figure 1. Weight-bearing anteroposterior (AP) foot X-ray illustrating angles associated with congenital hallux valgus: hallux valgus angle (HVA): 30° , intermetatarsal angle (IMA): 16° , distal metatarsal articular angle (DMAA): 31° .

preoperative American Orthopaedic Foot & Ankle Society Metatarsophalangeal-Interphalangeal Score (AOFAS MTP-IP) score was 28.^[4]

Surgical Technique

Preoperative osteotomy planning is illustrated in Figures 2A and 2B. The patient underwent surgery under general anesthesia, with a tourniquet applied while in a supine position with the hip elevated. A side support apparatus was used to maintain the foot in a plantigrade position. After disinfection with povidone-iodine, the surgery began with osteotomy lines marked under fluoroscopic guidance.

A dorsal longitudinal incision was made to access the proximal metatarsal via a subperiosteal approach. A dome-shaped proximal osteotomy was outlined.^[5] The foot was then repositioned in plantigrade alignment, and the osteotomy line was weakened using a 0.9 mm Kirschner wire inserted perpendicular to the axial plane. The dome osteotomy was not yet completed at this stage. A lateral incision was made to perform a reverse “U” capsulotomy,^[6] and the bunion was excised using a mini saw. A dome-shaped distal osteotomy was then marked on the dorsal cortex.^[7]

The foot was again placed in a plantigrade position, and the distal osteotomy line was weakened with Kirschner wires, taking care not to penetrate the plantar cortex. The osteotomy line was aligned parallel to the axial plane of the foot.^[6] A mini saw was used to perform the plantar cortex osteotomy, while a needle facilitated conjoint tendon release and medial capsulotomy. After finalizing the osteotomy lines, a thin osteotome was used to complete the osteotomies. Corrections were made under fluoroscopic guidance, followed by temporary fixation with Kirschner wires and subsequent stabilization using two mini locking plates. Capsulorrhaphy and soft tissue procedures were then performed. The tourniquet was released, bleeding was controlled, and the incision was sutured. Finally, the foot was wrapped in an elastic bandage.

Follow-Up

On the first postoperative day, the patient began ambulating with double crutches without weight-bearing and initiated isometric quadriceps and ankle pump exercises. Sutures were removed at two weeks, and partial weight-bearing was introduced by the sixth week. She resumed wearing shoes by the third postoperative month. Postoperative weight-bearing anteroposterior and lateral foot X-rays at three months demonstrated significant angular corrections (Fig. 3A-B). By the sixth month, the AOFAS MTP-IP score had increased to 82.

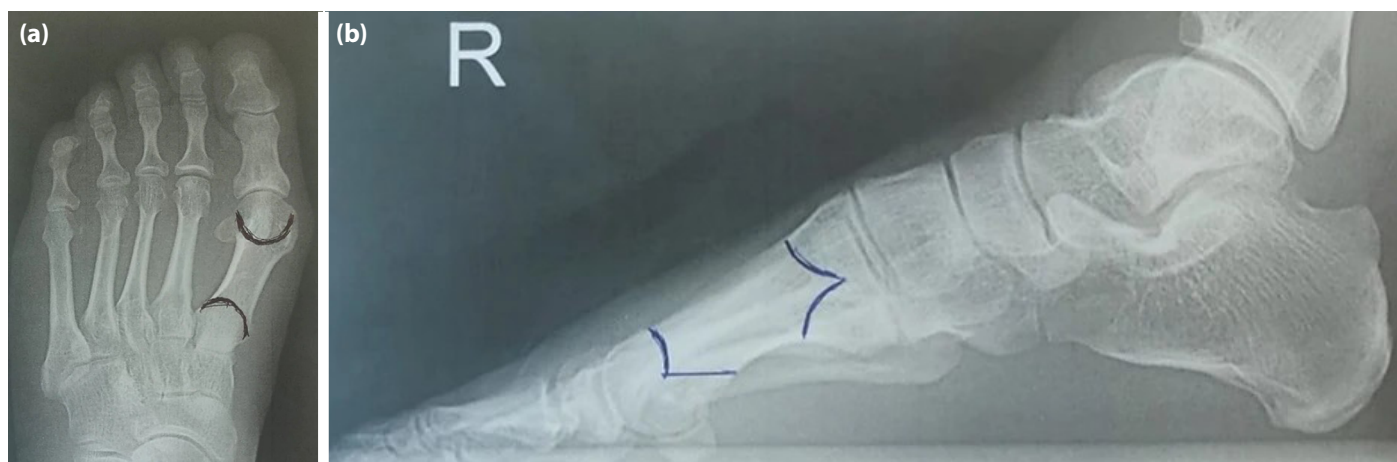

Figure 2. Preoperative planning of osteotomy lines. **(a)** Dorsal view, **(b)** Lateral view.

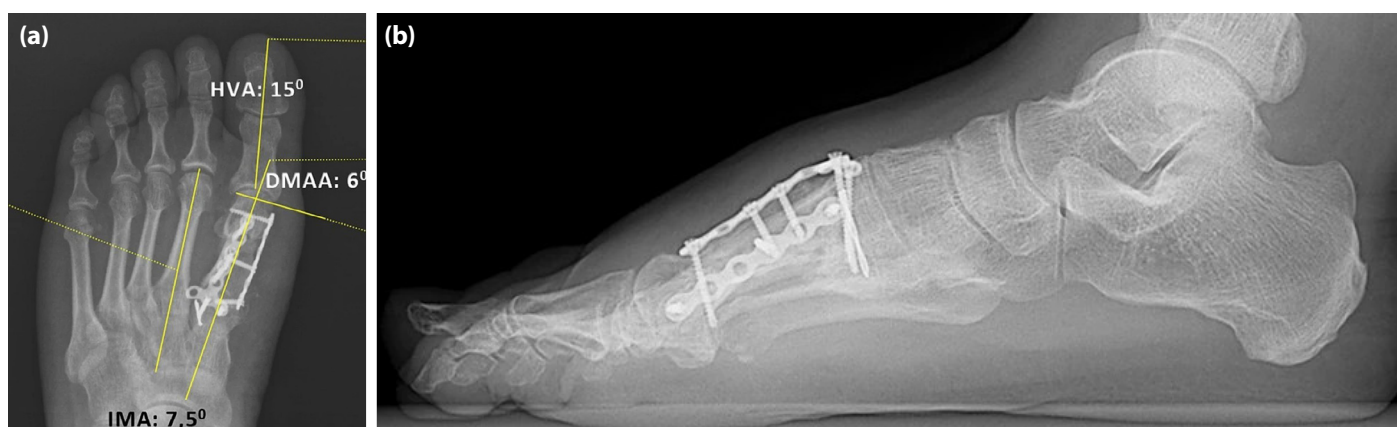

Figure 3. Postoperative weight-bearing X-rays at three months. **(a)** Anteroposterior view showing hallux valgus angle (HVA): 15°, intermetatarsal angle (IMA): 7.5°, distal metatarsal articular angle (DMAA): 6°. **(b)** Lateral view.

DISCUSSION

This case report presents a dome-based modification of the double osteotomy technique for the first metatarsal in HV with a congruent joint. The proximal metatarsal osteotomy utilizes a classic dome configuration,^[8] while the distal metatarsal osteotomy integrates elements of both the reverse L-shaped osteotomy^[6] and the dome osteotomy,^[7] thereby maximizing the advantages of the dome technique.

Previous studies have demonstrated the effectiveness of dome osteotomy in treating mild to moderate HV, both proximally and distally.^[7,8] Mirza et al.^[8] reported improvements in the HVA and IMA following proximal dome osteotomy, while Tonbul et al.^[7] documented corrections in HVA, DMAA, and IMA using a distal dome osteotomy.

Although the metatarsal shortening associated with traditional methods, the chevron osteotomy remains a commonly used

technique among surgeons.^[3] When combined with a medial closed-wedge osteotomy, it can reduce the DMAA, though often at the cost of stability. Additionally, distal metatarsal osteotomies carry a risk of osteonecrosis at the metatarsal head.^[9] Various modifications to the chevron osteotomy have been introduced to address these concerns.^[3, 10]

Espinosa et al.^[6] introduced the reverse L-shaped osteotomy for the distal metatarsal, which offers advantages such as preservation of metatarsal length. In contrast, the current technique modifies the dorsal cortex cut to a dome shape while maintaining a reverse L configuration for the plantar cortex. This proposed dome-based distal metatarsal osteotomy provides enhanced stability, preserves metatarsal length, eliminates the need for grafting, increases the contact surface for improved healing, and minimizes proximity to the sesamoid bone grooves.

There are some limitations to this technique. Although it introduces a double incision line, the risk of avascular necrosis remains a concern.^[3, 10] The double incision itself can also be a source of pain. Recurrence continues to be a potential risk in the surgical treatment of this deformity. The choice of fixation method—whether Kirschner wire or plate and screw—may influence clinical outcomes; however, plate fixation generally provides greater stability with this technique.

In conclusion, the dome-based double osteotomy combines the advantages of both dome and reverse L-shaped osteotomies. Dome-based double osteotomy of the first metatarsal in HV cases with a congruent joint may offer a viable solution for ensuring proper alignment. Further clinical studies are warranted to evaluate long-term outcomes.

Ethics Committee Approval: Ethics committee approval was obtained from Giresun Training and Research Hospital Ethics Committee (Approval Number: E-53593568-771-254354756, Date: 24.09.2024).

Author Contributions: Concept – K.A.; Design – K.A.; Supervision – K.A.; Resource – K.A.; Materials – K.A.; Data Collection and/or Processing – K.A.; Analysis and/or Interpretation – K.A.; Literature Review – K.A.; Writing – K.A.; Critical Review – K.A.

Conflict of Interest: The author have no conflicts of interest to declare.

Informed Consent: Written informed consent was obtained from the patient.

Use of AI for Writing Assistance: Was used for English grammar check.

Funding: The author declared that this study received no financial support.

Financial Disclosure: The authors declared that this study has received no financial support.

Peer-review: Externally peer-reviewed.

REFERENCES

- Peterson HA, Newman SR. Adolescent bunion deformity treated with double osteotomy and longitudinal pin fixation of the first ray. *J Pediatr Orthop* 1993;13(1):80—4. [\[CrossRef\]](#)
- Aytekin K, Bostan B, Balta O, Kurnaz R, Aşçı M, Bilgiç E, et al. Dome Osteotomy Results for Correction of Cubitus Varus Deformity. *Türkiye Klinikleri J Med Sci* 2015;35(3):157—65. [\[CrossRef\]](#)
- Nica M, Cretu B, Ene R, Serban B, Cîrstoiu C. Review of current hallux valgus management options. *ROJOST* 2019;2(2):130—38. [\[CrossRef\]](#)
- Kalaycıoğlu O, Ayanoğlu T, Yılmaz ÖF, Turhan MT. A cross-cultural adaptation and validation of the Turkish version of American Orthopaedic Foot and Ankle Society Metatarsophalangeal-Interphalangeal Scale (AOFAS-MTP-IP) for the hallux. *Jt Dis Relat Surg* 2023;34(2):305—14. [\[CrossRef\]](#)
- Petratos DV, Anastasopoulos JN, Plakogiannis CV, Matsinos GS. Correction of adolescent hallux valgus by proximal crescentic osteotomy of the first metatarsal. *Acta Orthop Belg* 2008;74(4):496—502.
- Espinosa N, Meyer DC, Campe AV, Hemly N, Vienne P. A new modified distal first metatarsal osteotomy for the treatment of hallux valgus deformity: The reversed L-shaped osteotomy. *Tech Foot Ankle Surg* 2006;5(3):190—7. [\[CrossRef\]](#)
- Tonbul M, Baca E, Adaş M, Ozbaydar MU, Yurdoğlu HC. Crescentic distal metatarsal osteotomy for the treatment of hallux valgus: a prospective, randomized, controlled study of two different fixation methods. *Acta Orthop Traumatol Turc* 2009;43(6):497—503. [\[CrossRef\]](#)
- Mirza HA, Al-Iedani MS, Al-Shamari AL, Majeed GH. Comparison between dome and wedge osteotomy in management of hallux valgus deformity. *Al-Qadisiyah Med J* 2016;12(22):49—58. [\[CrossRef\]](#)
- Meier PJ, Kenzora JE. The risks and benefits of distal first metatarsal osteotomies. *Foot Ankle* 1985;6(1):7—17. [\[CrossRef\]](#)
- Lewis RJ, Feffer HL. Modified chevron osteotomy of the first metatarsal. *Clin Orthop Relat Res* 1981;(157):105—9. [\[CrossRef\]](#)